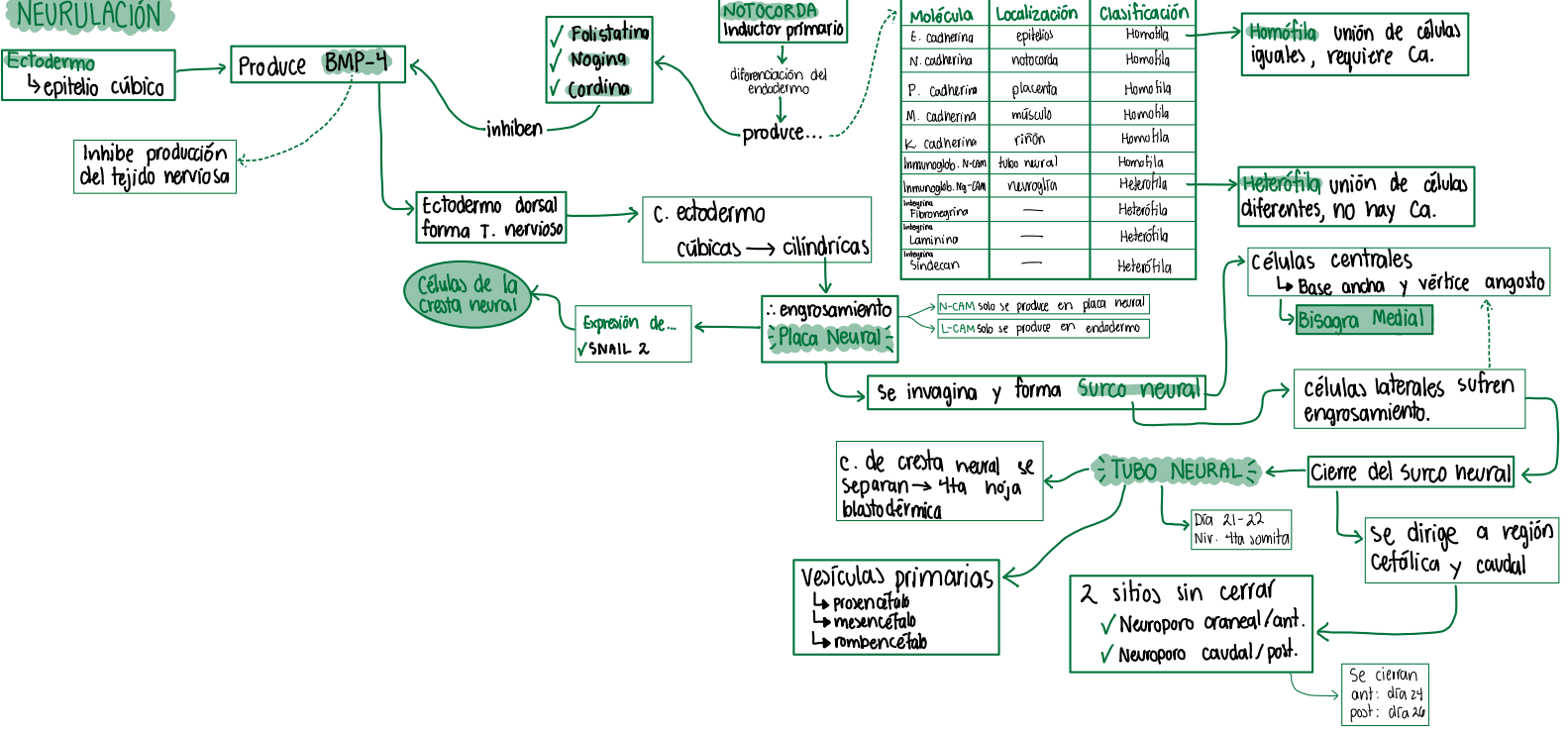
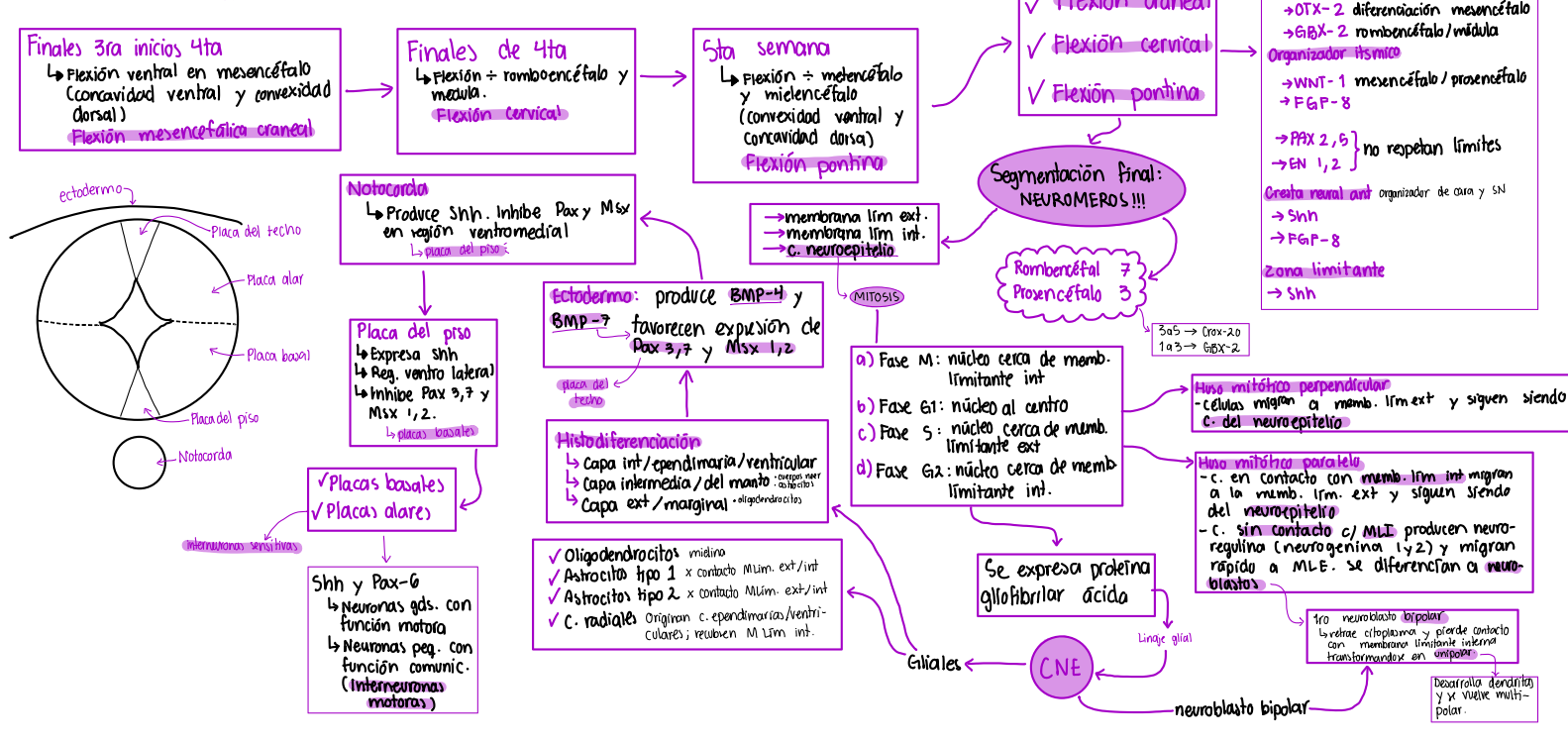


NEURULACIÓN



VESÍCULAS SECUNDARIAS



MÉDULA ESPINAL